

ALVEOLAR WOUND HEALING IN RATS FED ON HIGH SUCROSE DIET

María A. Baró, Marina R. Rocamundi, Javier O. Viotto, Ruth S. Ferreyra

Department of Oral Biology. School of Dentistry. Córdoba National University.

ABSTRACT

The potential for bone repair is influenced by various biochemical, biomechanical, hormonal, and pathological mechanisms and factors such as diet and its components, all of which govern the behavior and function of the cells responsible for forming new bone. Several authors suggest that a high sucrose diet could change the calcium balance and bone composition in animals, altering hard tissue mineralization. The mechanism by which it occurs is unclear. Alveolar healing following tooth extraction has certain characteristics making this type of wound unique, in both animals and humans.

The general aim of this study was to evaluate and quantify the biological response during alveolar healing following tooth extraction in rats fed on high sucrose diets, by means of osteocyte lacunae histomorphometry, counting empty lacunae and measuring areas of bone quiescence, formation and resorption.

Forty-two Wistar rats of both sexes were divided into two groups: an experimental group fed on modified Stephan Harris diet (43% sucrose) and a control group fed on standard balanced diet. The animals were anesthetized and their left and right lower molars extracted. They were killed at 0 hours, 14, 28, 60 and 120 days. Samples were fixed, decalcified in EDTA and embedded in paraffin to prepare sections for optical microscopy which were stained with hematoxylin/eosin.

Histomorphometric analysis showed significant differences in the size of osteocyte lacunae between groups at 28 and 60 days, with the experimental group having larger lacunae. There were more empty lacunae in the experimental group at 14 days, and no significant difference in the areas of bone activity.

A high sucrose diet could modify the morphology and quality of bone tissue formed in the alveolus following tooth extraction.

Key words: Tooth Socket, bone, dietary sucrose.

CICATRIZACIÓN ALVEOLAR EN RATAS CON DIETA RICA EN SACAROSA

RESUMEN

El potencial de reparación ósea está influenciado por una variedad de mecanismos bioquímicos, biomecánicos, hormonales, patológicos y factores como la dieta y sus componentes; todos rigen el comportamiento y función de las células encargadas de formar nuevo hueso. Varios autores sugieren que una dieta rica en sacarosa, podría cambiar el balance del calcio y la composición ósea en animales, alterando la mineralización de tejidos duros. El mecanismo por el cual esto se produce no es claro. La cicatrización alveolar post extracción reúne características particulares que la convierten en una herida única, en animales y en humanos.

El objetivo general de este trabajo fue evaluar y cuantificar la respuesta biológica durante la cicatrización alveolar post extracción en ratas con dieta rica en sacarosa; mediante la histomorfometría de lagunas osteocíticas, recuento de lagunas vacías y medición de zonas de reposo, neoformación y resorción ósea.

Se utilizaron 42 ratas Wistar, de ambos sexos, que fueron divididas en dos grupos: grupo experimental, alimentadas con

dieta modificada de Stephan Harris (43% de sacarosa) y grupo control alimentadas con dieta balanceada estándar. Se anestesiaron los animales y se extrajeron primeros molares inferiores, derecho e izquierdo, luego fueron sacrificados a las 0hs., 14, 28, 60 y 120 días. Las muestras obtenidas fueron fijadas, descalcificadas con EDTA e incluidas en parafina y se obtuvieron cortes para microscopía óptica que fueron coloreados con hematoxilina/eosina.

El análisis histomorfométrico mostró diferencias significativas de tamaño entre lagunas osteocíticas de ambos grupos a los 28 y 60 días siendo de mayor tamaño en los experimentales, se encontraron mayor cantidad de lagunas vacías en experimentales a los 14 días y no hubo diferencias significativas en las superficies de actividad ósea.

Una dieta rica en sacarosa podría producir modificaciones en la morfología y calidad del tejido óseo que se forma en el alveolo post extracción dentaria.

Palabras clave: Alvéolo dentario, hueso, dieta rica en sacarosa

INTRODUCTION

Following tooth extraction, a series of events takes place in the human alveolus which makes this type of wound unique in the body. The broken surface covering exposes the bone and clot to a septic cavity containing microorganisms (saprophytes or pathogens), which may upset the biological bal-

ance¹. In addition, the entire periodontium is irreversibly damaged and healing takes place by secondary intention².

The potential for bone repair is influenced by a range of external factors, such as diet, which affects the behavior and function of the cells responsible for forming new bone.

Osteocytes, the most plentiful cells in bone tissue^{3,4}, are involved in control of extracellular concentration of calcium and phosphorus and in the process of adaptive remodeling through cell-cell interactions in response to the local environment, thus preserving bone homeostasis and ensuring bone vitality. They are found in the osteocyte lacunae and connect by means of a network of cytoplasmic processes through cylindrical canaliculi to blood vessels and other osteocytes, forming a bone micro-circulation system, sending and receiving signals to and from other osteocytes, osteoblasts and bone-lining cells⁵.

Several studies have shown that a high sucrose diet alters mineral metabolism in humans, inducing changes in calcium balance⁶. In experimental animals, changes in bone composition have been observed,⁷ as well as variations in the mineralization of hard tissues, teeth and bones⁸, taking into account that their formation processes are considerably similar⁹. Regarding dentin, it was found that there is a reduction both in its degree of mineralization¹⁰ and in the amount formed¹¹; regarding bone tissue, there is alteration of mechanical properties^{12,13}, with marked reductions in concentrations of calcium and phosphorous, bone density and resistance to fracture in rats of both sexes¹⁴. All the literature consulted shows bone alterations produced by a high sucrose diet in different bones in experimental animals; but there is no description of what happens or how this kind of diet affects the maxillaries or the alveolus following tooth extraction in humans or experimental animals.

The mechanism by which high sucrose diet negatively affects bone metabolism is still unclear. It has been reported that it might cause glucose-intolerance and hyperinsulinemia, which indirectly produce deleterious effects on the bone¹⁵. The consequences of this kind of diet on calcium absorption, bone calcium content and bone mechanical properties are still a matter of controversy.

The aims of this study were to assess and quantify the effects produced by a high sucrose diet on bone tissue by means of a histomorphometric study of the osteocyte lacunae in the bone tissue, surface areas of bone undergoing resorption and new formation, and quantity of osteocytes and empty lacunae per mm² during alveolar wound healing following tooth extraction in rats.

MATERIALS AND METHODS

Forty-two Wistar rats of both sexes were fed on the same standard feed from birth to weaning (21 days), after which they were divided into two groups of 21, a control group and an experimental group. The control group was fed a standard balanced diet (Gepsa Feeds, Grupo Pilar, Bs. As., Argentina) and the experimental group was fed a modified Stephan Harris diet¹⁶ with high sucrose content (43%). Each group comprised four sub-groups of 5 rats (3 females and 2 males), to be killed at 14, 28, 60 and 120 days, plus one rat to be killed at 0 hours.

The food for the experimental group was prepared once a week because it did not contain any preservatives. The ingredients and quantities were strictly controlled. Food and water were provided *ad libitum*.

The rats were identified according to group. For the extractions they were given an intra-peritoneal injection of 8 mg/100g ketamine chlorhydrate (Ketalar®, Parke Davis, Morris Plains, NJ) and 1.28 mg/100g xylazine (Rompun®, Bayer, Leverkusen, Germany). The treatment area was disinfected with 0.12% chlorhexidine digluconate solution¹⁷.

Right and left lower first molars were extracted using a dental explorer as an extraction elevator after peeling back the soft tissues, and a mosquito clamp to complete the extraction^{18,19}.

Rats were euthanized at 0 hours, 14, 28, 60 and 120 days by anesthetizing with ketamine chlorhydrate plus xylazine and perfusion with 10% buffered formalin.

The whole lower maxillary was extracted, a sagittal section was performed at its mid-point and the pieces were preserved in formalin at 4° C for 24 hours²⁰.

The right half was decalcified in EDTA at neutral pH for +/- 30 days, with radiographic control of the process. Samples were embedded in paraffin and 10 serial sections, 5 to 7 µm thick, were cut on a plane across the alveolus zone corresponding to two of the roots of the extracted molar – a modification of the original experimental model by Guglielmotti et al.²¹ in which the section was obtained at the level of the mesial root of the extracted molar. The sections were stained with hematoxylin/eosin and the following parameters measured under conventional optical microscopy (Olympus BX 50F4): total lacuna area, lacuna perimeter, quantity of empty lacunae per mm² and bone surfaces.

Histomorphometry

Eight to 10 microscope images at 40X were digitalized from each case and at least 50 true lacunae were taken randomly, following a zigzag pattern^{22,23}. Areas of 18861 μm^2 were evaluated using the Image Pro Plus program. The microscope-camera optical system was calibrated for each objective with a micro-rule (Carl Zeiss). The area of the complete lacunae (without canalicular projections) was measured directly using the image analyzer. Uncomplete and empty lacunae were avoided.(Fig. 1).

Empty lacunae were counted using 40X images and with relation to the number of osteocytes per mm^2 .

Bone surfaces

In order to measure the percentages of bone quiescence, new formation and resorption, the alveolar area corresponding to the bisector of the angle formed between the external cortical wall and a horizontal line passing through the roof of the mandibular canal was considered.^{17,18} The images were digitalized at 20X and the areas were marked manually, considering the following histological parameters:

Quiescent surface: smooth bone surface with inactive atrophic-looking osteoblasts attached to the bone wall (Fig. 2).

Area undergoing new formation: surface of bone tissue with a lining of osteoid material and hypertrophic osteoblasts attached to it (Fig. 3).

Resorption area: eroded bone surface with Howship's lacunae, with or without osteoclasts (Fig. 4).

Results were statistically evaluated by means Student's T-test for mean areas of osteocyte lacunae, Chi Square for Areas of bone remodeling and Mann Whitney's test for quantity of empty lacunae per mm^2 .

RESULTS

Histomorphometric analysis

Morphological differences in the osteocyte lacunae were observed between groups at different times. The ones in the experimental group were more irregular, rounded and larger than those in the control group. Significant differences were found in mean areas at 28 and 60 days (Figs. 5, 6, 7 and 8). Table 1 shows the mean values for each group at all times. They were analyzed using Student's test, considering $p < 0.05$ as significant.

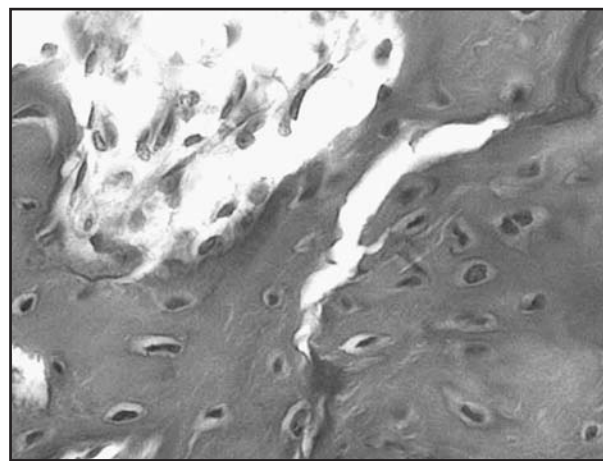


Fig. 1A: Microphotograph of osteocyte lacunae to be measured.

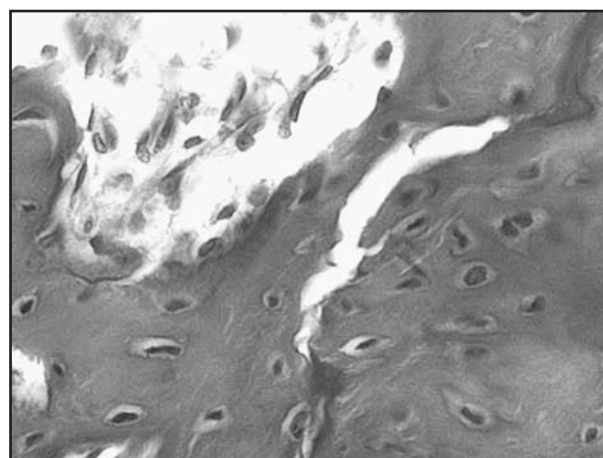


Fig. 1B: The same slide with lacunae selected semi-automatically for measurement. (hematoxylin/eosin – 40X).

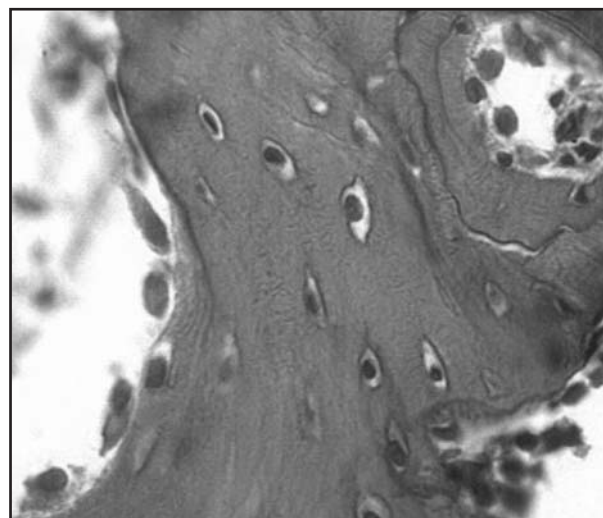


Fig. 2: Quiescent area with osteoblasts of atrophic appearance on the bone surface. (Hematoxylin/eosin – 40X).

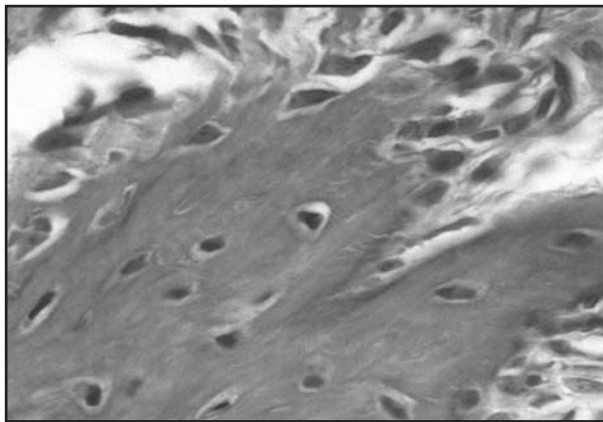


Fig. 3: Area of newly formed bone with hypertrophic osteoblasts and osteoid. (Hematoxylin/eosin – 40X).

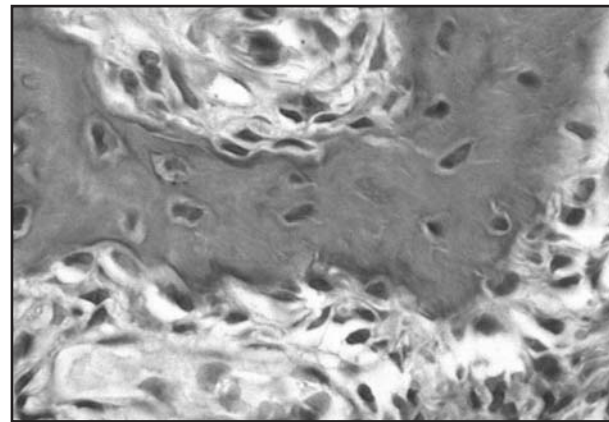


Fig. 4: Resorption area with Howship's lacunae. (Hematoxylin/eosin – 40X).

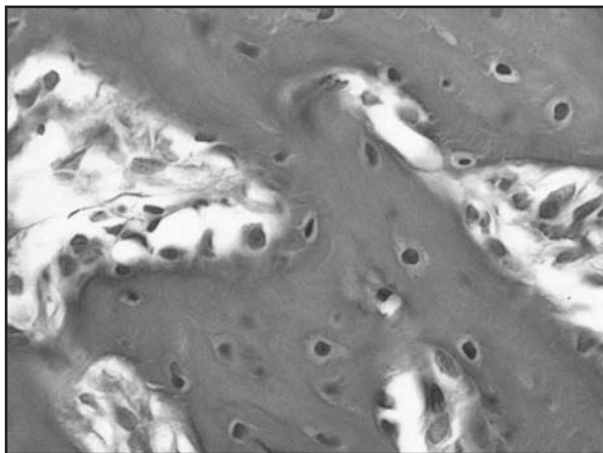


Fig. 5: Control at 28 days: the bone tissue has an orderly arrangement with clearly outlined, elliptical osteocyte lacunae of normal size containing osteocytes. (Hematoxylin/eosin – 40X).

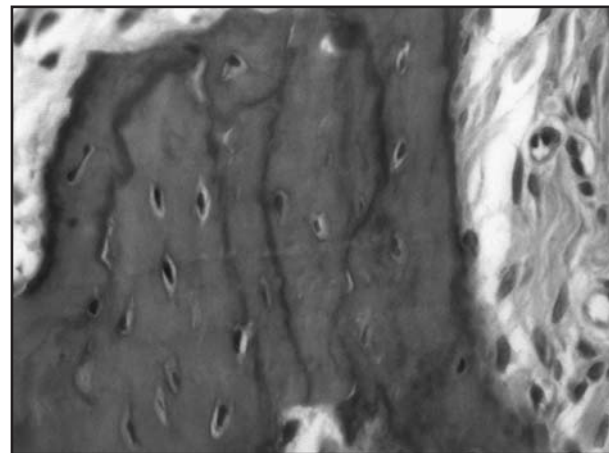


Fig. 6: Control at 60 days: osteocyte lacunae maintain their shape and are smaller than in controls at 28 days due to the change in the maturity of the bone tissue, which has basophilic lines of inversion and more compact appearance. (Hematoxylin/eosin – 40X).

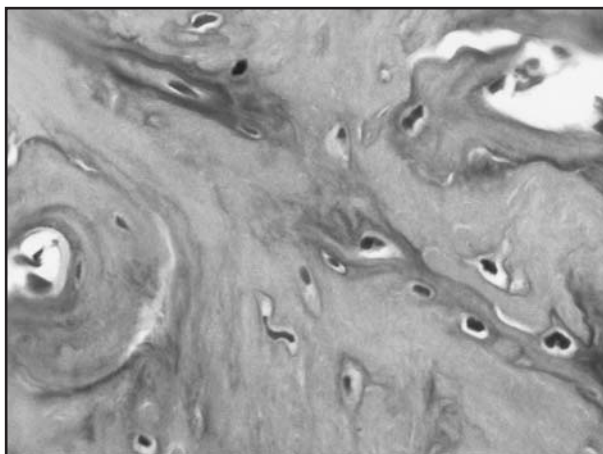


Fig. 7: Experimental at 28 days: inverse lines showing intensive bone remodeling; lacunae more irregular but clearly outlined and larger than in the controls. (Hematoxylin/eosin – 40X).

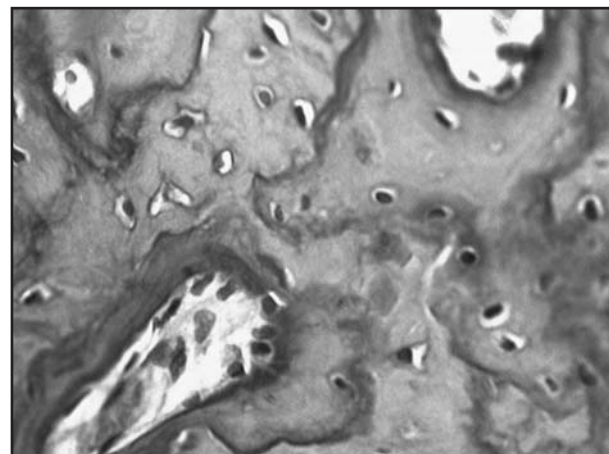


Fig. 8: Experimental at 60 days. Bone tissue with disorganized appearance, lacunae clearly larger than in controls, outlines poorly defined and morphology becomes irregular. (Hematoxylin/eosin – 40X).



Table 1: Mean areas and quantity of lacunae measured.

Time	14 days		28 days		60 days		120 days	
	Control N:5	Experimental N:5	Control N:5	Experimental N:5	Control N:5	Experimental N:5	Control N:5	Experimental N:5
Mean area (µm²)	54.0	53.3	48.4	52.6	43.3	46.6	46.0	46.7
Standard error	1.1	1.2	1.4	1.2	0.9	1.0	1.1	1.0
Mean deviation	19.97	21.09	25.31	21.06	16.20	17.75	19.53	18.08
Maximum	134.4	148.5	224.3	142.9	103.4	140.7	128.8	117.3
Minimum	16.6	18.7	13.3	16.6	13.2	14.0	11.5	9.5
Lacunae measured (n)	353	329	337	327	329	314	338	328
P value=	0.56		0.02*		0.01*		0.62	

(*) p<0.05

Analysis of number of osteocytes and empty lacunae per mm²

Empty lacunae were found at all study times in both groups (Fig. 9). The difference between experimental and control animals regarding quantity of empty lacunae compared to number of osteocytes per mm² was significant at 14 days. The values were contrasted by the Mann Whitney non-parametric test. Quantity of osteocytes per mm² was higher in the control group than in the experimental group at all times. Table 2 provides all values.

affected by sucrose intake. Our study shows negative effects on the quality of newly formed bone in the alveolus following tooth extraction in animals fed on a diet containing 43% sucrose.

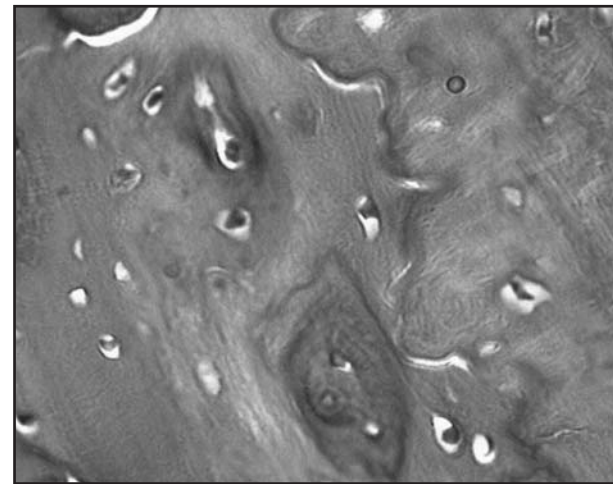


Fig. 9: Microphotograph of an experimental case showing presence of several empty lacunae. (Hematoxylin/eosin - 40X).

Analysis of bone surface areas

Percentages of areas with bone remodeling and different times were contrasted using the Chi-square test, but no significant difference was found.

DISCUSSION

Different studies have described the noxious effects on bone tissue of excessive sucrose intake²⁴. Tjäderhane *et al.*¹⁵ explain that all mineralized tissues are

Table 2: Quantity of empty lacunae with relation to quantity of osteocytes per mm².

Time	Quantity of osteocytes per mm²			Mann Whitney's Test Empty lacunae per mm²			
	Mean value		Statistical contrast	Mean value		Statistical significance	
	Control N:20	Experimental N:20		Control N:20	Experimental N:20		
14 days	1643	1591	14 days	65	113	0.04	*p < 0.05
28 days	1651	1395	28 days	88	107	0.08	Non sig.
60 days	1392	1390	60 days	122	101	0.20	Non sig.
120 days	1395	1391	120 days	72	80	0.82	Non sig.



Alveolar bone wound healing provides a sustainable model for studying bone formation in rats and may be considered a sensitive indicator of bone formation in normal conditions, as reported by Guglielmotti and Cabrini²¹ and Devlin¹⁹, and under other conditions, as reported by Gorustovich (2004, 2008)^{17,20} for alveolar bone histomorphometry with boron-deficient diet.

Some histological analyses suggest that at 21 days of alveolar wound healing the alveolus is occupied by a thin network of trabecular bone²⁵. Elsubeihi²⁶ reports that the process ends in the eighth week. However, Guglielmotti et al.²⁷ report maximum reticular bone formation and maximum alveolar volume at 14 days after extraction, young bone formation at 30 days and mature lamellar bone alveolar filling at 60 days, by quantifying the alveolar response with an image analyzer. Our study agrees with this but follows bone formation and maturation up to 120 days, when bone sclerosis is very noticeable in the experimental cases. Studies by Hara *et al.*²⁸ and Lockwood²⁹ on high sucrose diets and by Van Schothorst³⁰ on a high lipids diet, showed that these kinds of diet produce hyperinsulinemia, resistance to insulin and increase in plasma glucose levels. Holl and Allen³¹ reported that sucrose intake increases urinary excretion of calcium, sodium and zinc, with renal inhibition of calcium resorption. Clemens and Karsenty³² reported that the osteoblast is an important target of insulin for controlling whole-body glucose homeostasis and regulating the osteocalcin activation mechanism to produce bone resorption.

The size of osteocyte lacunae may increase due to various factors. Ferreyra et al.³³ showed enlarged per-

ilacunae associated to the application of orthodontic forces. Bozal *et al.*³⁴ reported osteocyte response to mechanical stimuli and inflammatory factors, which produce enlargement of their lacunae by osteolytic resorption, but with no change in cell volume. Krishnan and Davidovitch³⁵ describe osteocyte capacity to change its micro-environment in response to mechanical load. Thus, the change in size of osteocyte lacunae is related to the rigidity of the bone matrix, under normal conditions within a physiological range of size and density, for mechanical control of the forces applied on the bone tissue³⁶.

Quing and Bonewald³⁷ reported that the osteocyte has access to a very large area of its lacuna and the removal of just one Ångström (Å) of mineral per osteocyte may significantly affect circulation and systemic ion levels. In a review of the literature on osteocytic osteolysis, Tetia and Zalloneb³⁸ infer that it may be related to bone mineral homeostasis.

The significant differences in histomorphometry of osteocyte lacunae that we found in the alveolus following extraction may be related to the regulation of bone remodeling and to changes in the osteocyte micro-environment in response to a diet which alters mineral metabolism and the way in which bone tissue adapts in order to maintain control of homeostasis.

To conclude, excessive sucrose intake produces modifications in the morphology and quality of newly formed bone tissue in the alveolus after tooth extraction in rats, but further studies are needed to analyze and understand the molecular and cellular mechanisms that take place in it.

ACKNOWLEDGMENTS

The authors would like to thank the Department of Pathology at the School of Dentistry at Córdoba National University.

CORRESPONDENCE

Dr. María Anastasia Baró
Villarrica 1155 Barrio Residencial América
CP 5012, Córdoba, Argentina
natibaro@hotmail.com

REFERENCES

1. Felzani R. Cicatrización de los tejidos con interés en cirugía bucal: revisión de la literatura. *Acta Odontol Venez* 2005; 43:310-318.
2. Lopez J. *Cirugía Oral*. Interamericana, McGraw-Hill. Madrid, 1992;262-322.
3. Aarden EM, Burger EH, Nijweide PJ. Function of osteocytes in bone. *J Cell Biochem* 1994;55:287-99.
4. Burger EH, Klein-Nulend J. Mechanotransduction in bone - role of the lacunocanalicular network. *FASEB J*. 1999; 13:S101-S12.
5. Gomez de Ferraris M, Campos Muñoz A. *Histología y embriología bucodental*. 2º Ed. Editorial Médica Panamericana. Madrid 2002;339-384.
6. Ericsson Y, Angmar-Mansson B, Flores M. Urinary mineral ion loss after sugar ingestion. *Bone Miner* 1990;9:233-237.
7. Li K-C, Zernicke RF, Barnard RJ, Li AF-Y. Effects of a high fat-sucrose diet on cortical bone morphology and biomechanics. *Calcif Tissue Int* 1990;47:308-313.
8. Tjäderhane L, Bäckman T, Larmas M. Effects of sucrose and xylitol on dentin formation and caries in rat molars. *Eur J Oral Sci* 1995;103:166-171.



9. Linde A, Goldberg M. Dentinogenesis. *Crit Rev Oral Biol Med* 1993;4:679-728.
10. Tjäderhane L. The effects of high sucrose diet on dentin minerals measured by electron probe microanalyzer (EPMA) in growing rat molars. Quintessence Publishing Tokyo 1996; 293-297.
11. Anitua E, Ortiz Andía I. Un nuevo enfoque en la regeneración ósea: plasma rico en factores de crecimiento (P.R.G.F). Ed. Vitoria. Madrid, 2000.
12. Bostrom M, Yang X, Koutra I. Biologics in bone healing. *Curr Op Orthop* 2000;11:403-412.
13. Hollinger JO, Buck DC, Bruder SP. Biology of bone healing: Its impact on clinical therapy. In: Lynch SE, Genco RJ, Marx RE (ed). *Tissue engineering. Applications in maxillofacial surgery and periodontics*. Quintessence Publishing Co, Inc. Illinois 1999;17-44.
14. Aarden EM, Burger EH, Nijweide PJ. Function of osteocytes in bone. *J Cell Biochem* 1994;55:287-99.
15. Tjäderhane L, Hietala EL, Huumonen S, Larmas M. The effect of high sucrose diet on mineralized tissues. In: Pandalai SG (ed). *Recent research development in nutrition. Research Signpost* 2000;3:1-26
16. Stephan RM. Effects of different types of human foods on dental health in experimental animals. *J Dent Res* 1966; 45:1551-1561.
17. Gorustovich A, Steimetz T, Nielsen F, Guglielmotti MB. Histomorphometric Study of Alveolar Bone Healing in Rats Fed a Boron-Deficient Diet. *Anatomical Record*. 2008; 291:441-447.
18. Guglielmotti MB, Ubios AM, Cabrini RL. Alveolar wound healing after X-irradiation: a histologic, radiographic and histometric study. *J Oral Maxillofac Surg* 1986; 44:972-976.
19. Devlin H. Early bone healing events following rat molar tooth extraction. *Cells Tissues Organs* 2000; 167:33-37.
20. Gorustovich A, Veinsten F, Costa OR, Guglielmotti MB. Histomorphometric evaluation of the effect of bovine collagen granules on bone healing. An experimental study in rats. *Acta Odontol Latinoam* 2004;17:9-13.
21. Guglielmotti MB, Cabrini R. Alveolar wound healing and ridge remodeling after tooth extraction in the rat: a histologic, radiographic, and histometric study. *J Oral and Maxillofac Surg* 1985;43:359-364.
22. Meunier P, Bernard J. Morphometric analysis of periosteocytic osteolysis. In *bone histomorphometry. Fist International Workshop* 1973;278-287.
23. Baró M, Ferreyra R, Rocamundi M, Nemer K, Crosa M. Histomorphometric study of interradicular bone in patients with periodontal disease. *Acta Odontol Latinoam* 2003; 16:3-7.
24. Carvalho A, Nakamune A, Biffe B, Louzada M. High-sucrose effect on bone structure, hardness and biomechanics in an obesity model using Wistar male rats. *J.Morphol.Sci.* 2012; 29:32-37.
25. Calixto R, Teofilo J, Brentegani L, Lamano Carvalho T. Alveolar Wound Healing after Implantation with a Pool of Commercially Available Bovine Bone Morphogenetic Proteins (BMPs) - A Histometric Study in Rats. *Braz Dent J* 2007;18:29-33.
26. Elsubeihi ES, Heersche JNM. Quantitative assessment of postextraction healing and alveolar ridge remodelling of the mandible in female rats. *Arch Oral Biol* 2004;49:401-412.
27. Guglielmotti MB, Ubios AM, Cabrini RL: Alveolar wound healing alteration under uranyl nitrate intoxication. *J Oral Pathol* 1985;14:565-572.
28. Hara SY, Ruhe RC, Curry DL & McDonald RB. Dietary sucrose enhances insulin secretion of aging Fischer 344 rats. *J Nutr* 1992;122:2196-2203.
29. Lockwood B & Eckhert CD. Sucrose-induced lipid, glucose, and insulin elevations, microvascular injury, and selenium. *Am J Physiol* 1992;262:144-149.
30. Van Schothorst E, Bunschoten A, Schrauwen P, Mensink R, Keijer J. Effects of the high fat, low- versus high-glycemic index diet: retardation of insulin resistance involves adipose tissue modulation. *Faseb J* 2009;23:1093-1101.
31. Holl M, Allen L. Sucrose ingestion, insuline response and mineral metabolism in humans. *J Nutr* 1987;117:1229-1233.
32. Clemens T, Karsenty G. The Osteoblast: An Insulin Target Cell Controlling Glucose Homeostasis. *J. Bone Miner. Res.* 2011;26:677-680
33. Ferreyra RS, Ubios M, Gendelman H, Cabrini R. Enlargement of periosteocytic lacunae associated to mechanical forces. *Acta Odont Latinoamer* 2000;13:31-38.
34. Bozal CB, Fiol JA, Ubios AM. Osteocytic lacunae enlarge immediately in response to a stimulus. *J Dent Res* 2002; 81:B-9.
35. Krishnan V, Davidovitch Z. Cellular, molecular, and tissue-level reactions to orthodontic force. *Am J Orthod Dentofacial Orthop* 2006;129:460-469.
36. Yeni Y, Vashishth D, Fyhrie D. Estimation of bone matrix apparent stiffness variation caused by osteocyte lacunar size and density. *J Biomech Eng* 2001;123:1-10.
37. Quing H, Bonewald L. Osteocyte remodeling of the perilacunar and pericanalicular matrix *Int J Oral Science* 2009; 1:59-65.
38. Teti A, Zalloneb A. Do osteocytes contribute to bone mineral homeostasis? Osteocytic osteolysis revisited. *Bone* 2009;44:11-16.

