

In reply to the letter to the editor "Tele(oral)medicine: A new approach during the COVID-19 crisis"

Dear Editor

We would like to congratulate Villa et al for the recent published letter to the editor (Villa, Sankar, & Shiboski, 2020), emphasizing the use of tele(oral)medicine as an effective diagnostic tool (Estai, Kanagasigam, Tennant, & Bunt, 2018), which could be useful in the current time of crisis. The COVID-19 pandemic and the social isolation measures mandated by health authorities have led to a reassessing of the professional practices in our Dental College.

We report a case reflecting a suitable use of telemedicine in Oral Medicine. A general dental practitioner, working in a small Patagonian village (more than 1,000 km away from our institution), referred us a case using Instagram and WhatsApp. It was a 7-year-old female with chief complaint of spontaneous gingival bleeding, with no previous medical conditions. The clinical pictures sent showed multiple haemorrhagic bullae, petechial lesions, and gingival bleeding (Figure 1). A thorough anamnesis was performed remotely, where previous febrile episodes and generalized weakness were

recorded. The provisional diagnoses were haematological conditions such as leukaemia, idiopathic thrombocytopenic purpura (ITP) and haemorrhagic dengue. The last one was also considered due to an increased number in dengue cases in our country (Ayala, Vera, Chiappero, Almirón, & Gardenal, 2020). We asked for a full blood count of the child, which revealed a severe thrombocytopenia with a platelet count of less than 10,000 platelets per microlitre, with other values within normal limits. Thus, an urgent referral to haematology was indicated, where ITP with oral involvement was diagnosed.

The quarantine allowed us to distinguish tele(oral)medicine as a remote diagnostic method to help patients with oral diseases. However, a rational use should be encouraged, recognizing its limitations. On that regard, from our experience one of the most important drawback is the lack of tactile assessment. In agreement with Villa et al., we believe that future research efforts should address Telemedicine as a diagnostic method, also considering relevant issues such as the quality of the photographic record, legal, remunerative aspects, and others.

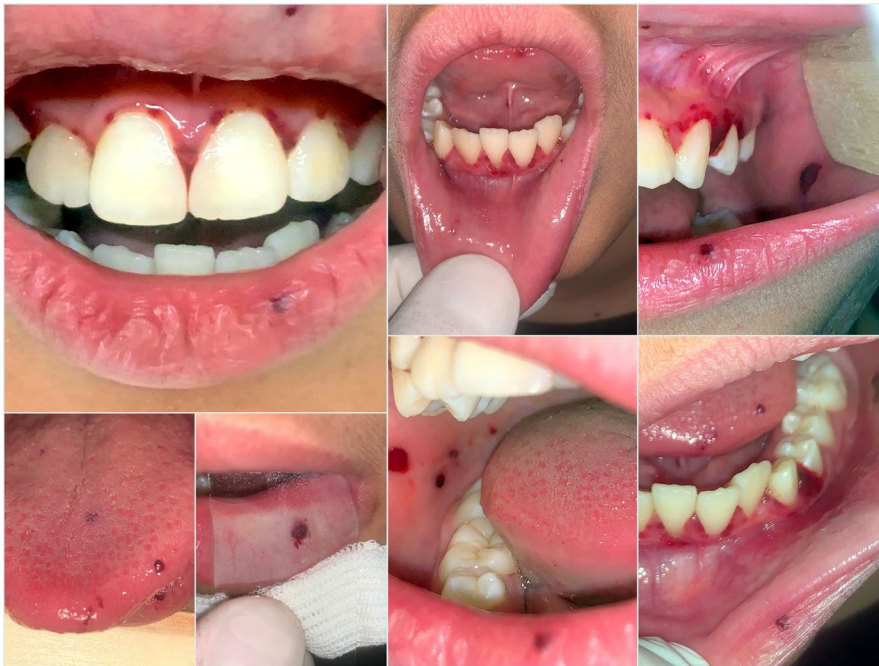

FIGURE 1 Clinical records were obtained using a smartphone by the general practitioner who referred us the case by Telemedicine. The most important clinical findings were spontaneous gingival bleeding, haemorrhagic bullae on both sides of the buccal mucosa, and ecchymosis. Diascopy was remotely indicated by our group, and the blood extravasation was demonstrated with this technique

KEYWORDS





idiopathic thrombocytopenic purpura, oral medicine, remote diagnosis, telemedicine

ACKNOWLEDGEMENT

The authors would like to thank Dr Sebastián Ezequiel Morales for the referral of the case by telemedicine.

AUTHOR CONTRIBUTION

Gerardo M. Gilligan: Conceptualization; Data curation; Formal analysis; Methodology; Resources; Visualization; Writing-original draft; Writing-review & editing. **Eduardo D. Piemonte:** Conceptualization; Formal analysis; Writing-review & editing. **Jerónimo P. Lazos:** Formal analysis; Supervision; Writing-review & editing. **René L. Panico:** Supervision; Visualization; Writing-review & editing.

Gerardo M Gilligan 
Eduardo D Piemonte 
Jerónimo P Lazos 
René L. Panico 

*Oral Medicine Department, Facultad de Odontología,
Universidad Nacional de Córdoba, Haya de la Torre SN,
Córdoba, 5000, Argentina*

Correspondence

Gerardo M. Gilligan, Oral Medicine Department, Facultad de Odontología, Universidad Nacional de Córdoba, Haya de la Torre SN, Córdoba 5000, Argentina.
Email: ggilligan@unc.edu.ar

ORCID

Gerardo M Gilligan  <https://orcid.org/0000-0002-5201-1444>
Eduardo D Piemonte  <https://orcid.org/0000-0001-5955-1139>
Jerónimo P Lazos  <https://orcid.org/0000-0002-0881-9614>
René L. Panico  <https://orcid.org/0000-0001-6427-1254>

REFERENCES

- Ayala, A. M., Vera, N. S., Chiappero, M. B., Almirón, W. R., & Gardenal, C. N. (2020). Urban populations of *Aedes aegypti* (Diptera: Culicidae) from central Argentina: Dispersal patterns assessed by Bayesian and multivariate methods. *Journal of Medical Entomology*, 1–8. <https://doi.org/10.1093/jme/tjaa017>
- Estai, M., Kanagasigam, Y., Tennant, M., & Bunt, S. (2018). A systematic review of the research evidence for the benefits of teledentistry. *Journal of Telemedicine and Telecare*, 24, 147–156.
- Villa, A., Sankar, V., & Shiboski, C. (2020). Tele(oral)medicine: A new approach during the COVID-19 crisis. *Oral Diseases*, 1–2.